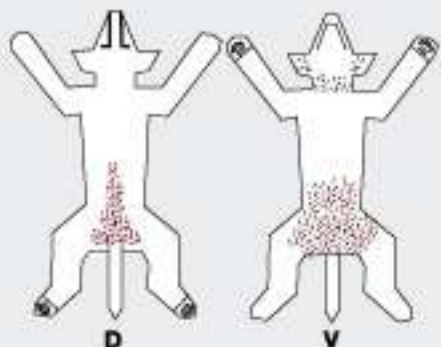
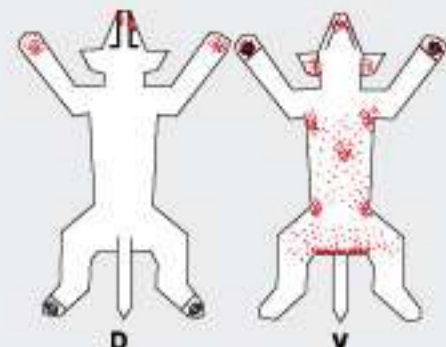


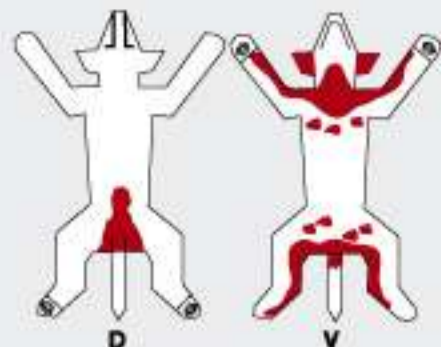
Dermatitis por hipersensibilidades



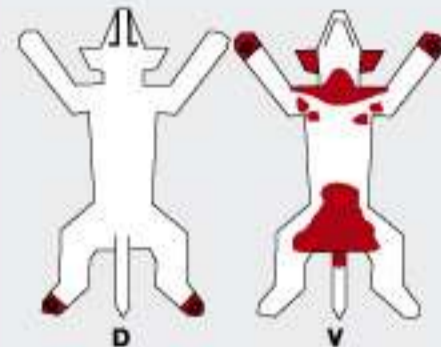
Dermatitis Alérgica a las pulgas
Estadio II



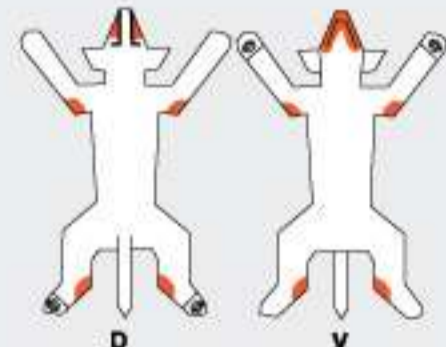
Alopecia Canina
Estadio II



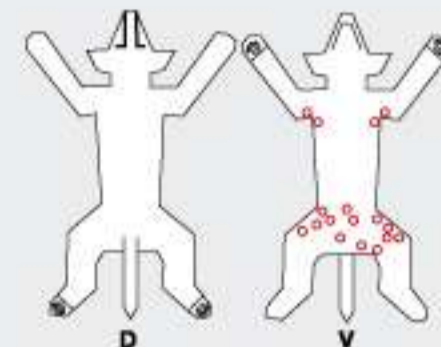
Alergia Alimentaria



Dermatitis por contacto
(del piso)

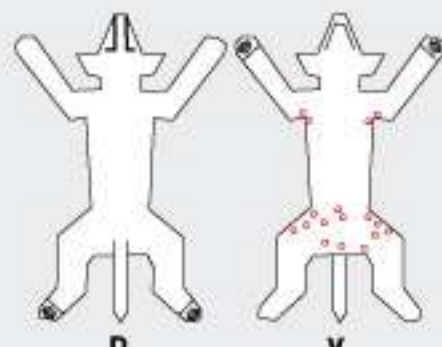


Dermatitis por contacto
(plástico)

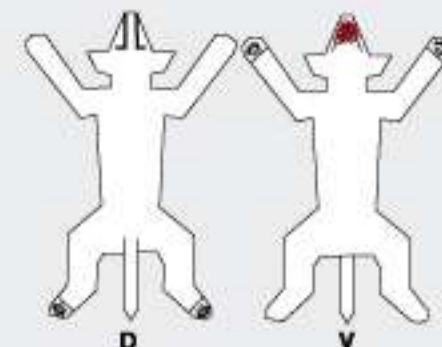


Hipersensibilidad Bacteriana
Estadio II

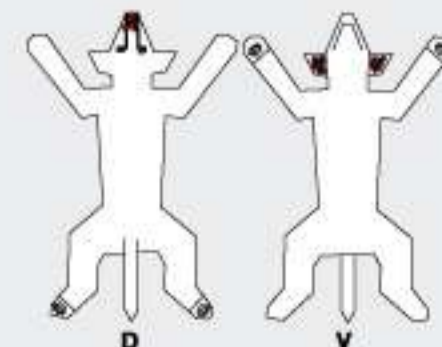
Dermatitis bacterianas



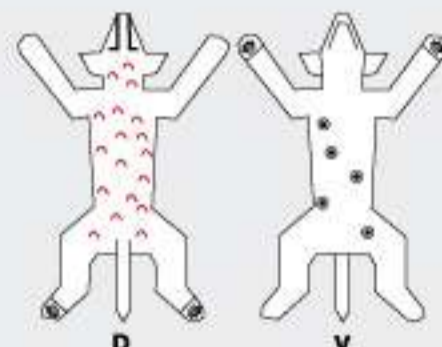
Impétigo



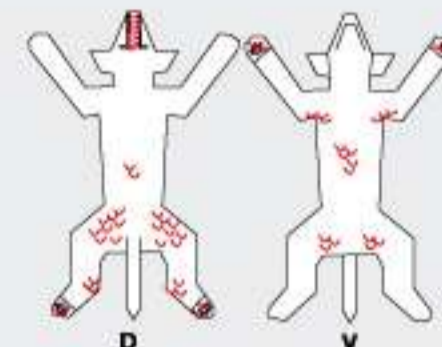
Foliculitis y forunculosis del mentón



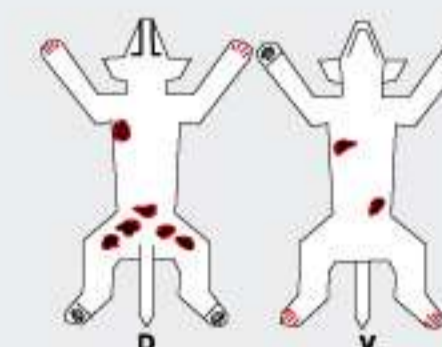
Foliculitis y forunculosis nasal



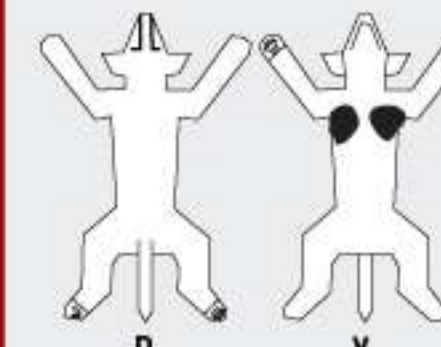
Foliculitis bacteriana superficial



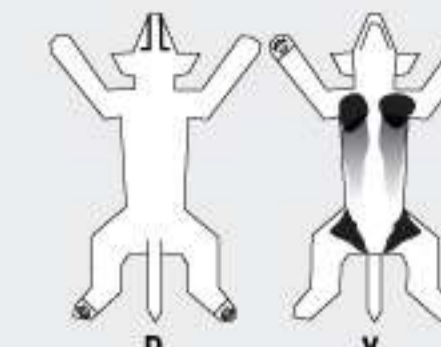
Foliculitis, forunculosis y celulitis



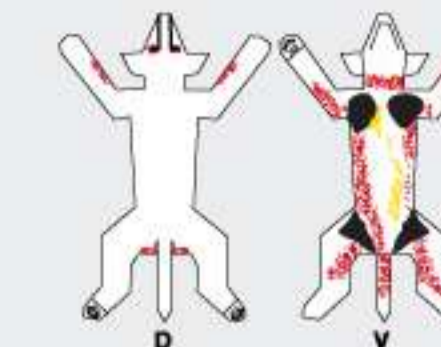
Pododermia del Ovejero alemán



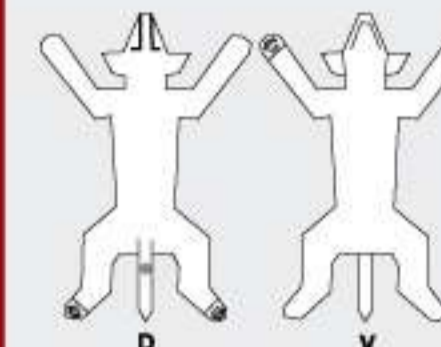
Acanthosis nigricans
Estadio I



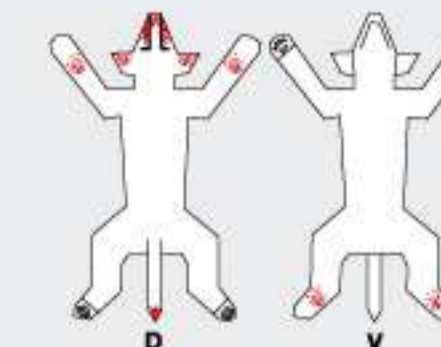
Acanthosis nigricans
Estadio II



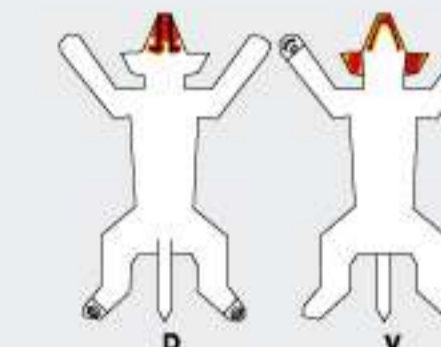
Acanthosis nigricans
Estadio III



Hiperplasia de la glándula de la cola

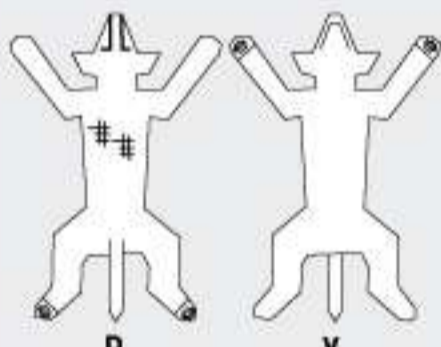


Dermatomyositis

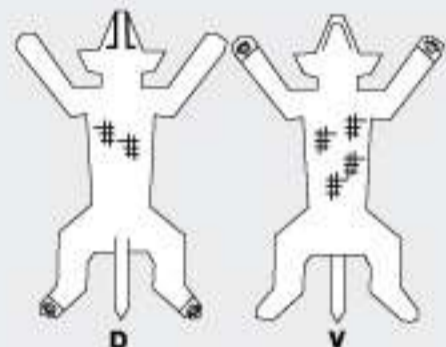


Celulitis juvenil

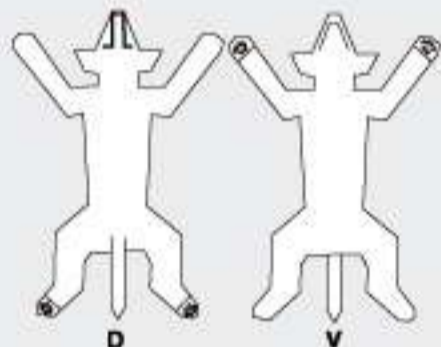
Dermatosis por alteración de glándulas sebáceas y otras



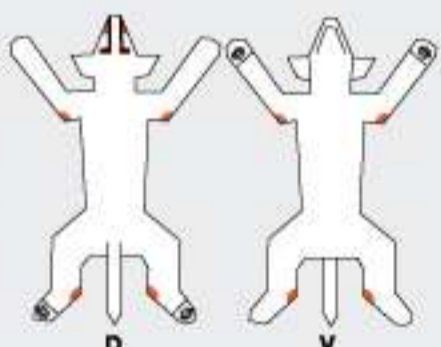
Dermatosis que responde a la Vit A
Estadio I



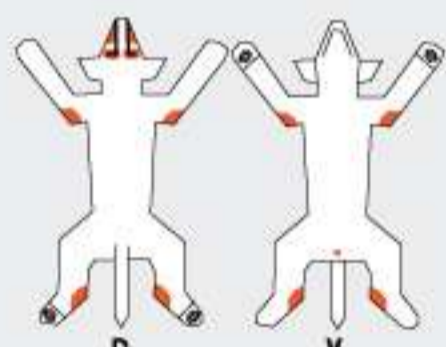
Dermatosis que responde a la Vit A
Estadio II



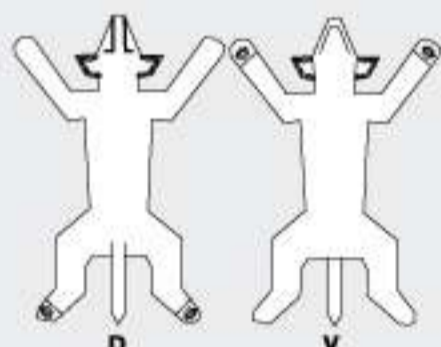
Hiperqueratosis nasodigital



Dermatosis que responde al Zinc
Estadio I

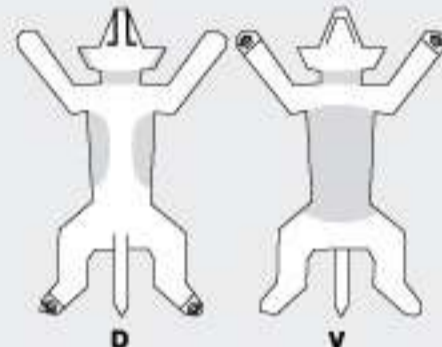


Dermatosis que responde al Zinc
Estadio II

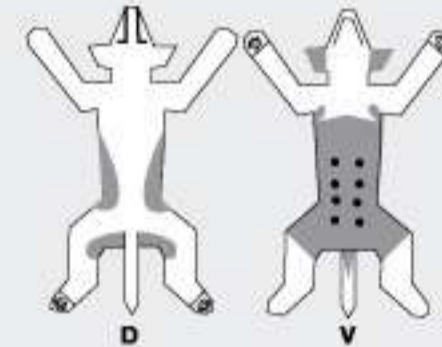


Seborrea del borde de las orejas

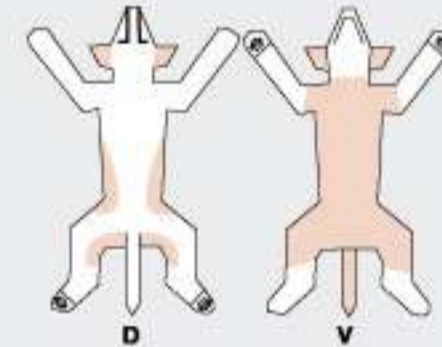
Dermatosis de origen hormonal



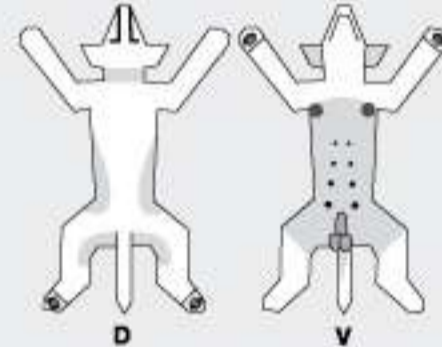
Hipotiroidismo



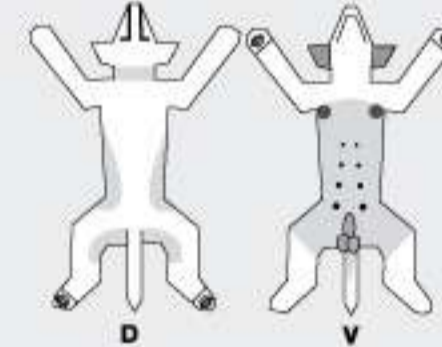
Hiperestrogenismo femenino



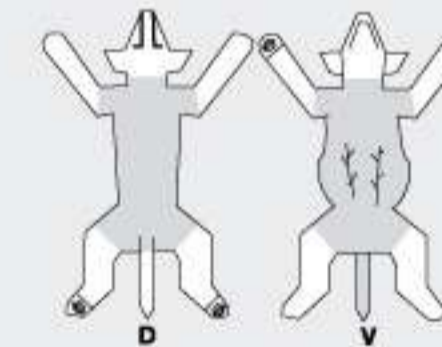
Hipoestrogenismo



Tumor de Células de Sertoli

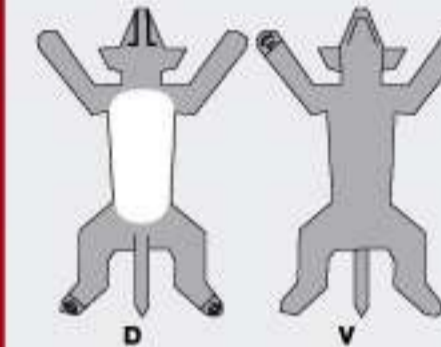


Hipoandrogenismo

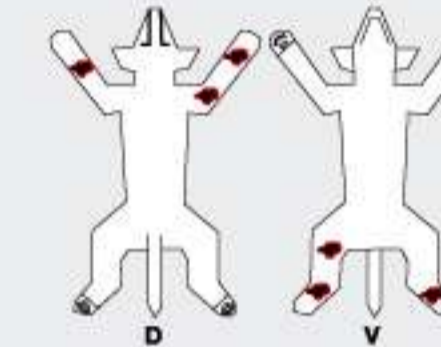


Hiperadrenocorticism

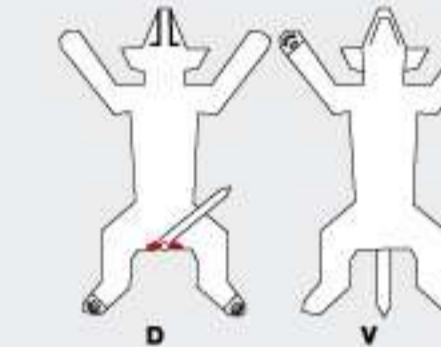
Misceláneas



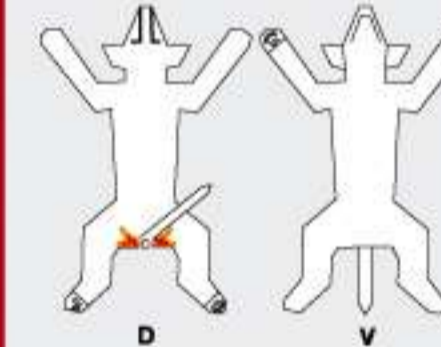
Alopecia por mutación de color



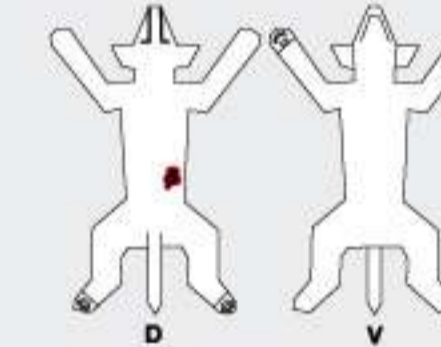
Dermatitis acral por lamido



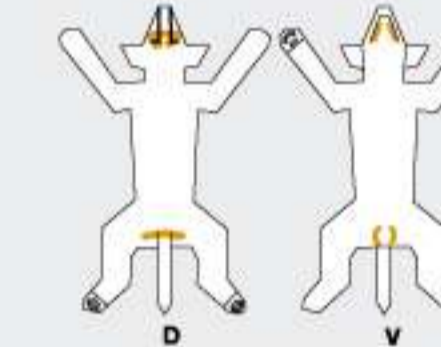
Enfermedad de los sacos anales



Fistulas perianales

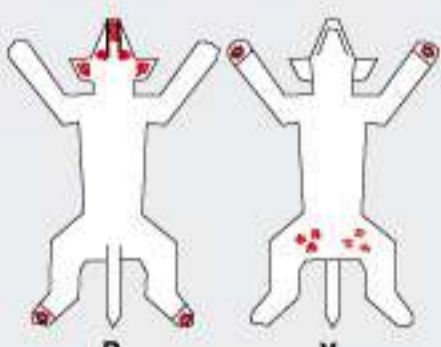


Dermatitis por succión del flanco

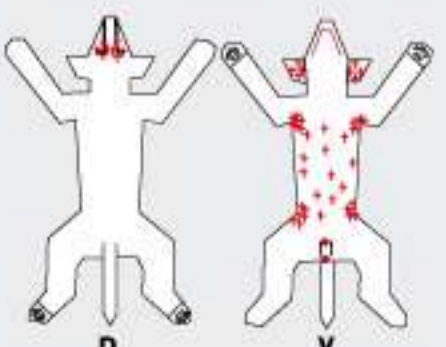


Dermatitis de los pliegues

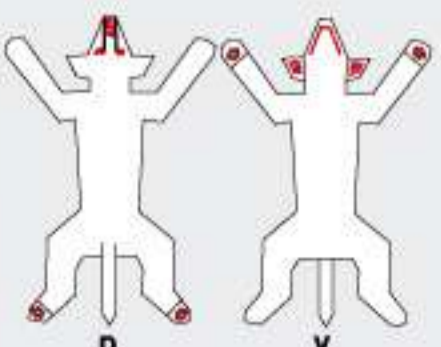
Dermatitis autoinmunes



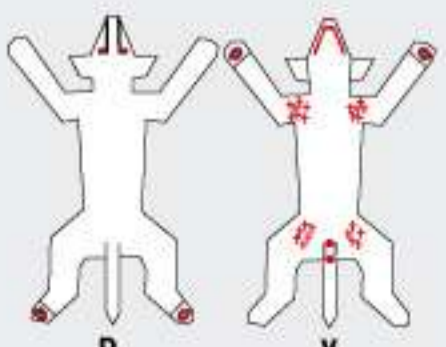
Pérfigo Foliáceo



Pérfigo Vulgaris

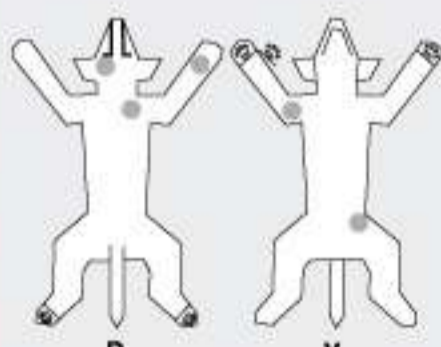


Lupus Discoide

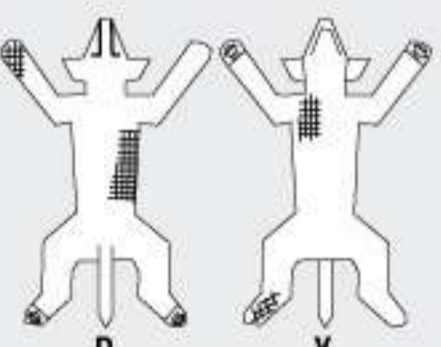


Pérfigoide Buloide

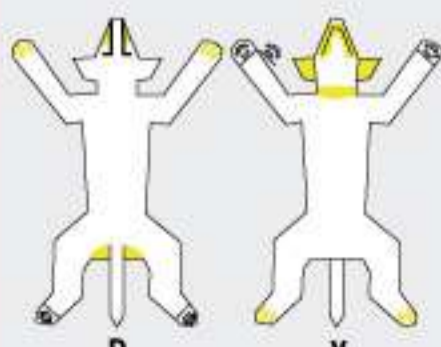
Dermatosis por hongos



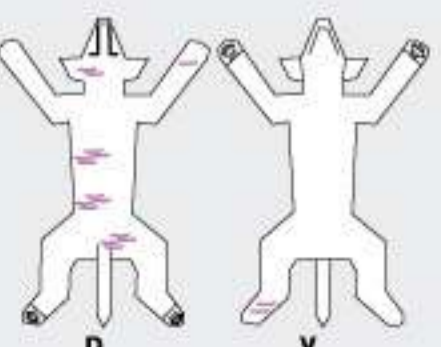
Dermatofitosis por Microsporium



Dermatofitosis por Tricofitos

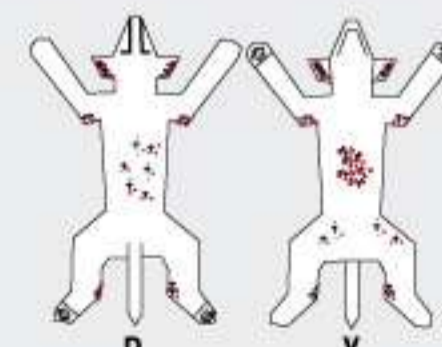


Dermatitis por Malassezia

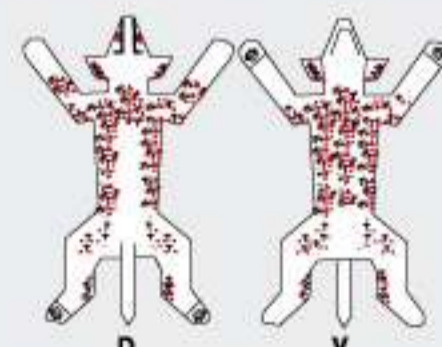


Esporotricosis

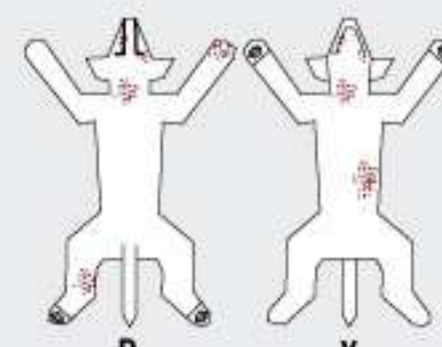
Dermatitis por ectoparásitos



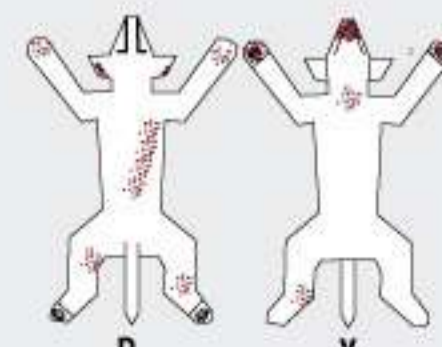
Sarna Sarcóptica
Estadio II



Sarna Sarcóptica
Estadio III



Demodicosis localizada



Demodicosis generalizada

Neo Vitapel®

El más efectivo tratamiento anticaída.
Para un pelo fuerte, con brillo
y una piel sana.



BROUWER

www.brouwer.com.ar